

Use of ERC-1671 Vaccine in a Patient with Recurrent Glioblastoma Multiforme after Progression during Bevacizumab Therapy: First Published Report

Daniela A Bota, MD, PhD; Daniela Alexandru-Abrams, MD; Chrystel Pretto, PhD; Florence M Hofman, PhD; Thomas C Chen, MD, PhD; Beverly Fu, NP; Jose A Carrillo, MD; Virgil EJC Schijns, PhD; Apostolos Stathopoulos, MD, PhD

Perm J 2015 Spring;19(2):March 1, 2015

<http://dx.doi.org/10.7812/TPP/14-042>

ABSTRACT

Objectives: Glioblastoma multiforme (GBM) is a highly aggressive tumor, which recurs despite resection, focal beam radiation, and temozolomide chemotherapy. At recurrence, the only second-line treatment approved by the US Food and Drug Administration is bevacizumab (Avastin). To date, no single agent has shown to extend the life of patients with progressive malignant gliomas after bevacizumab failure. Once the tumor recurs during bevacizumab therapy, it is universally fatal, with death occurring within a few weeks. ERC-1671 is an experimental treatment strategy, which uses the patient's own immune system to attack the tumor cells. We report preliminary data on the first human administration of ERC-1671 vaccination, under a single-patient, compassionate-use protocol, to a patient with progressive, bevacizumab-resistant GBM.

Methods: Treatment involved sequential administration to the patient of GBM tumor cells and cell lysates combined from three different donors with GBM, followed by the patient's own tumor cells and lysates.

Results: The patient survived for ten months after the vaccine administration without any other adjuvant therapy and died of complications related to his previous chemotherapies. The tissues collected after two vaccination cycles and at the time of death showed a robust immune response and no viable tumor.

Conclusion: These preliminary data strongly indicate that ERC-1671 could be effective in the treatment of progressive malignant gliomas. On the basis of these preliminary data, we are planning a larger study to assess the efficacy of ERC-1671 in the treatment of patients with recurrent GBM.

highly aggressive tumors is gross total resection followed by radiation therapy and temozolomide chemotherapy.¹⁻³ Unfortunately, gross total resection is difficult because of the highly infiltrative nature of these tumors and their common involvement of essential areas of the brain. Invariably, malignant gliomas recur, and second-line therapy with bevacizumab (Avastin), an antiangiogenic agent, is administered in an attempt to stall the progression of tumor growth.⁴ With this treatment, the median survival has improved to only 18 months in the last decade.^{1,3} Once glioblastoma multiforme (GBM) recurs during bevacizumab treatment, it is universally fatal, with survival rates less than a few weeks despite aggressive treatments.⁴ Therefore, additional forms of therapy are sorely needed to treat patients with malignant gliomas.⁵

Since 2000, immunotherapy has shown great promise for the treatment of cancer⁶ because the immune system can be induced to eradicate malignant cells.⁵⁻⁷ In addition, if successful in treating cancer in the initial phase, this method has the advantage of creating a memory response to prevent further tumor recurrences.⁶ In the past, research showed that proper activation of the immune response against cancer cells could prevent development of new cancer cells. For example, in colon cancer research, *in situ* analysis of tumor-infiltrating immune cells^{8,9} showed that tissues infiltrated with CD8⁺ T cells contributed to better patient survival.^{8,9} However, active vaccination for cancer therapy has shown modest results.⁵

In addition, the literature reports that tumors have effective strategies to evade a fully functional immune system.¹⁰ For example, researchers showed that the presence of major histocompatibility complex Class 1 on tumor cells can play a role in cancer resistance,¹¹ that the tumors may be unresponsive to interferons,¹⁰ and that tumor-induced immunosuppression can occur.¹² Furthermore, recent data indicated that patients with an overactive immune response, such as an autoimmune disease, have a better prognosis compared with patients with normal

INTRODUCTION

Malignant gliomas are the most common type of primary brain tumor, with an incidence of approximately 10,000 new cases annually in the US.¹ The standard treatment of these

Daniela A Bota, MD, PhD, is an Associate Professor of Neurology and Neurosurgery at the University of California, Irvine in the City of Orange. E-mail: dbota@uci.edu. **Daniela Alexandru-Abrams, MD**, is a Neurosurgery Resident at the University of California, Irvine Medical Center in the City of Orange. E-mail: danielaa@uci.edu. **Chrystel Pretto, PhD**, is the Laboratory Manager for Epitepoietic Research Corporation at the Scientific Park Crealys in Gembloux, Les Ines, Belgium. E-mail: pretto@ercbelgium.eu. **Florence M Hofman, PhD**, is a Professor of Pathology at the Keck School of Medicine, University of Southern California, Los Angeles. E-mail: hofman@usc.edu. **Thomas C Chen, MD, PhD**, is the Chief Medical Officer of Epitepoietic Research Corporation and a Professor of Neurosurgery at the Keck School of Medicine, University of Southern California, Los Angeles. E-mail: tcchen@usc.edu. **Beverly Fu, NP**, is a Neurological Oncology Nurse Practitioner in the Neurology Department of the University of California, Irvine Medical Center in the City of Orange. E-mail: dfu@uci.edu. **Jose A Carrillo, MD**, is an Assistant Professor of Neurology at the University of California, Irvine Medical Center in the City of Orange. E-mail: carrilj2@uci.edu. **Virgil EJC Schijns, PhD**, is the Chief Security Officer of Epitepoietic Research Corporation and a Professor of Immune Intervention in the Department of Cell Biology and Immunology at the Wageningen University in Netherlands. E-mail: virgil.schijns@wur.nl. **Apostolos Stathopoulos, MD, PhD**, is the Chief Executive Officer for Epitepoietic Research Corporation at the Scientific Park Crealys in Gembloux, Les Ines, Belgium and Chief Neurosurgeon, Department of Neurosurgery, Arlon Hospital, Belgium. E-mail: tstath@hotmail.com

immune systems.^{5,13,14} The IgG species from these patients were identified to share important homology with both human and microbial peptides.¹⁵ Also, four patients with malignant brain tumors went into remission after intracranial infections,¹⁶ and multiple patients had better outcomes and increased survival after wound infections.¹⁷ These findings led to the hypothesis that tolerance to tumor-associated antigens can be reversed by cross-reactivity against foreign homologous antigens.^{5,6}

Previous publications from our group have extensively studied this hypothesis in rodent models and demonstrated that administration of allogeneic glioma cells and syngeneic tumor cell lysates to rats induced rejection of malignant gliomas and provided protection against future recurrences.^{5,6} If one strain of rats (Sprague-Dawley) is injected with glioma tumor cells derived from a different rat strain (Fischer 344), the foreign (allogeneic) tumor cells will be rejected and no tumor will grow. However, if the same rats were then injected with glioma tumor cells generated in their strain (syngeneic), the previously allogeneic vaccinated groups were able to significantly reduce tumor growth, and complete rejection of tumors was noted in some rats. Using this principle, we hypothesized that if two patients have a tumor of a similar type and histologic grade, transplantation of tumor tissue from one patient to another might induce a robust immune response and expose the immune system to peptides shared between the two tumors, thus allowing the immune system to recognize and attack tumor-specific antigens.

In the present report, we translate to the clinical arena this original idea of using allorecognition and coadministration of syngeneic tumor antigens to patients to overcome the ability of the malignant gliomas to evade the immune system. We use the patient's immune system to recognize intact, same-species, nonself major histocompatibility complex molecules on the surface of donor cells and to directly eliminate the tumor cells by an immune-mediated response.⁶ This process is well documented and well described in acute allograft rejection.¹⁸ In this article, we present the first use of the ERC-1671 vaccine to treat a patient with advanced GBM whose cancer relapsed during bevacizumab treatment.

METHODS

Vaccine Production

ERC-1671 was manufactured under conditions of good manufacturing practices by Bio Elpida (Dardilly, France). Surgically removed GBM tissues provided the raw material. The tumor tissues were collected, under protocols approved by an institutional board review, in the operating room under aseptic conditions. The tumor specimens were transported in sterile culture medium and fully tested for viral infections, including human immunodeficiency virus, hepatitis B virus, hepatitis C virus, cytomegalovirus, syphilis, and human T-lymphotropic virus. The tumor samples were sent in temperature-controlled sealed packs to the good manufacturing practices site immediately after the surgery.

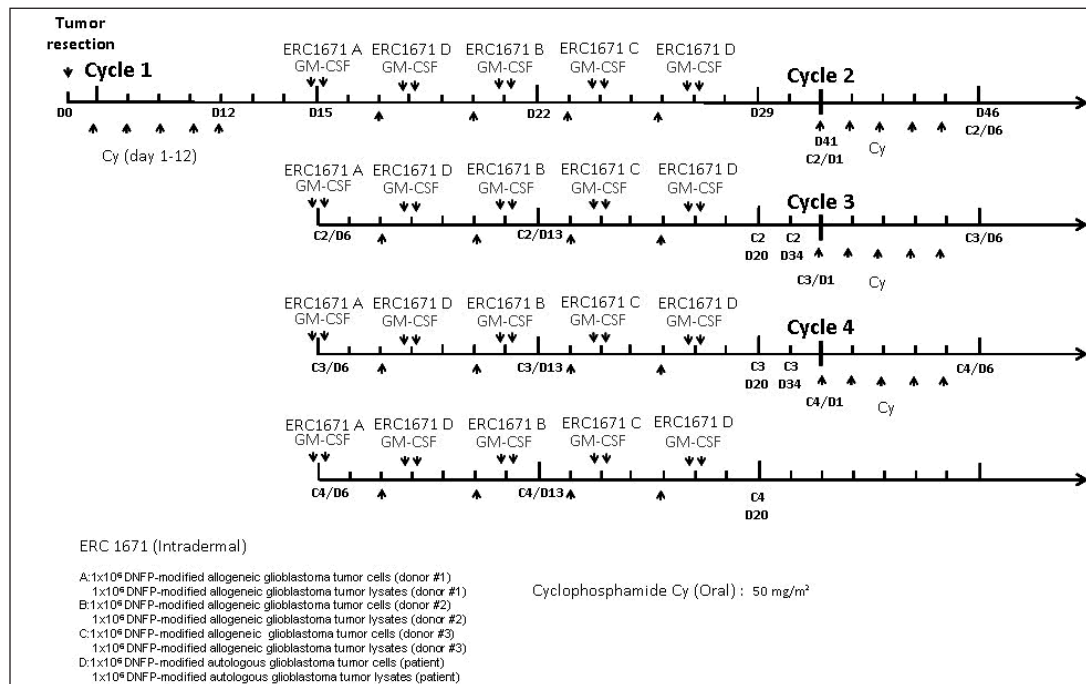


Figure 1. Treatment scheme for intradermal administration of ERC-1671 vaccine for patients with recurrent glioblastoma multiforme after failure to respond to bevacizumab therapy^a

^aERC-1671 doses A to C contained approximately 1 × 10⁶ dinitrophenol-modified allogeneic tumor cells and 1 × 10⁶ dinitrophenol-modified allogeneic tumor lysates from Donors 1 to 3, respectively. Dose D contained approximately 1 × 10⁶ dinitrophenol-modified autologous tumor cells and approximately 1 × 10⁶ dinitrophenol-modified autologous tumor lysates from the patient.

Cy = cyclophosphamide (50 mg/m²) orally; GM-CSF = granulocyte-macrophage colony-stimulating factor (sargramostim).

At the manufacturing site, the tumor was dissociated on a single-cell suspension, and the cells were haptenized using dinitrophenol. The haptenized cells were then separated into two different specimens, and one of the specimens was lysed to obtain the lysate component. Both the cellular component and the lysate component were then irradiated to make sure that none of the remaining tumor cells had the ability to replicate.

Treatment Scheme

The treatment process (Figure 1) involved 4 monthly cycles of vaccination with GBM tumor cells and lysates generated from 3 different donors with GBM (the allogeneic component) as well as from the patient's own tumor (the autologous component). ERC-1671 treatment was administered together with a manmade form of granulocyte-macrophage colony-stimulating factor, sargramostim (Leukine), as adjuvant therapy, following the oral administration of a low dose (50 mg/m²) of cyclophosphamide (Endoxan). This treatment combination was developed during the preclinical studies, and it produced the maximal tumor response in rats.

Each monthly cycle consisted of 5 intradermally administered treatment doses. One dose was composed of a freshly mixed shot of both a cellular component and a lysate component, stored in separate vials. The cell vial contained a suspension of 10⁵ to 10⁶ irradiated dinitrophenol-modified tumor cells, and the lysate vial contained the equivalent of a lysate of 10⁵ to 10⁶ irradiated dinitrophenol-modified tumor cells. The ERC-1671 A, B, and C product doses were prepared from 3 different GBM-affected donors, whereas the ERC-1671 D dose was derived from the patient's tumor. The monthly treatment was continued for as long as the tumor responded to treatment.

CASE STUDY

A 43-year-old man presented to the University of California, Irvine Medical Center in June 2008 with headaches, hiccups, fatigue, and hypersomnia. Magnetic resonance imaging (MRI) revealed a left frontal lobe tumor. He underwent craniotomy with gross total tumor resection (more than 95% of the contrast-enhancing area) on June 26, 2008. The histopathologic

analysis showed the diagnosis of GBM (World Health Organization Grade IV astrocytoma). From July 2008 to September 2008, the patient was treated with fractionated radiation therapy with concomitant temozolomide chemotherapy. The patient was maintained on 12 cycles of adjuvant temozolomide chemotherapy from September 2008 until October 2009. Because the patient was stable and the tumor did not demonstrate recurrence on neuroimages, the decision was made to follow his disease progression with serial brain MRIs and observation. In February 2010, tumor growth was noted on the brain MRI. The patient immediately underwent craniotomy with subtotal tumor resection (about 70% of the tumor was removed). The pathologic findings were consistent with GBM, with moderately high Ki-67 labeling index (Figure 2).

In March 2010, the patient began a clinical trial with bevacizumab (Avastin) and bortezomib (Velcade). His bortezomib therapy was discontinued after nine cycles, as required by the study protocol, but he continued to receive bevacizumab therapy. In March 2012, the patient experienced further tumor progression, as shown on his brain MRI, with the tumor now crossing the corpus callosum and progressing toward the left temporal area (Figure 3A). The patient underwent immediate debulking of the contrast-enhancing area and some of the adjacent abnormal fluid-attenuated inversion recovery (FLAIR) areas of his tumor (Figure 3B), which again showed pathologic findings consistent with GBM (Figures 2 and 4).

As no other options for his treatment-resistant, recurrent glioblastoma were available, an application for compassionate use of ERC-1671 was made to the US Food and Drug Administration with the patient's consent, and he was administered ERC-1671 vaccine under a single-patient protocol approved by that agency. The first cycle was administered immediately after resection, and the remaining 3 cycles were given at monthly intervals (Figure 1). After the second cycle of vaccination, a tumor biopsy was obtained to evaluate the treatment response. Because the biopsy specimen showed extensive inflammatory changes and very few proliferating tumor cells, the patient did not receive any adjuvant treatment in addition to the vaccine. Ten months after starting the ERC-1671 treatment and almost 11 months since

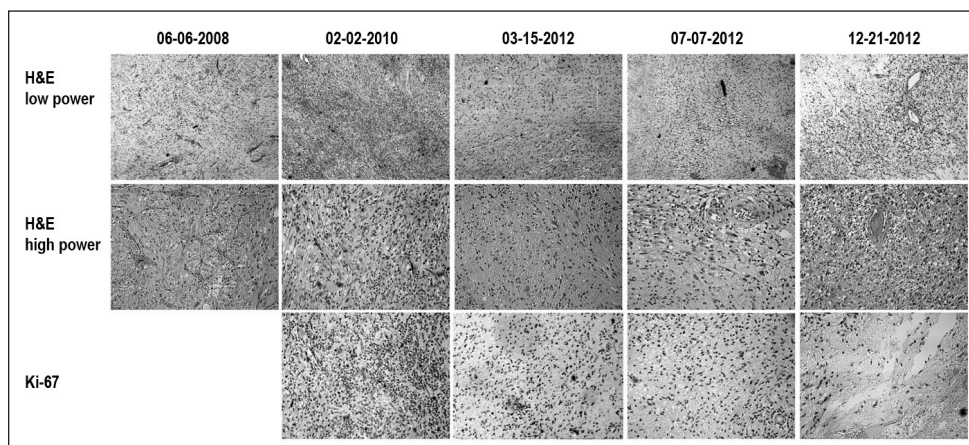


Figure 2. Histopathologic analysis of tumor specimens from surgery and autopsy. Specimens show progression of Ki-67 (bottom row) from high-power magnification (middle row, 20x) to low-power magnification (top row, 10x) after administration of 2 cycles of vaccination (March and July 2012), decreasing further after completion of vaccination, as evidenced by autopsy specimen in December 2012 (far-right column) staining with hematoxylin-eosin (H&E).

Figure 3. Magnetic resonance image (MRI) of the brain showing the tumor size before resection (A, E), after resection (B, F), end of vaccination Cycle 1 (C, G), end of Cycle 2 (D, H), end of Cycle 3 (I, J), and end of Cycle 4 (K, L). The MRI shows a slow increase in fluid-attenuated inversion recovery (FLAIR) signal (top row) and contrast enhancement (bottom row) over time (x-axis, in month/day/year format).

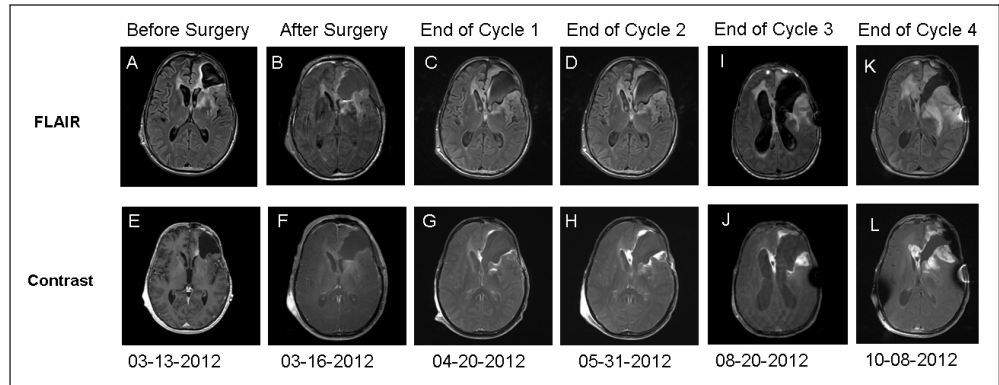
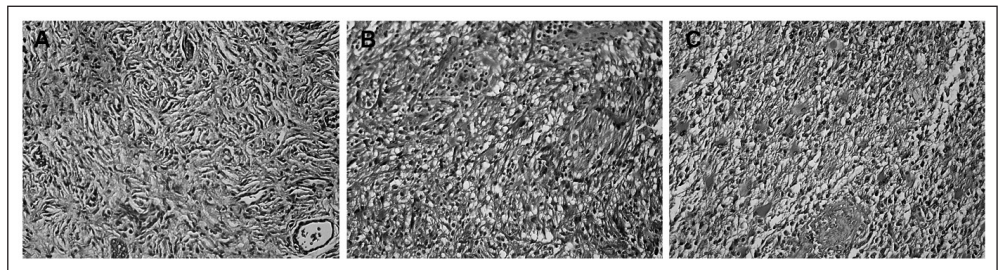


Figure 4. Histopathologic examination of tumor samples and immunohistochemical staining. Trichrome stain of specimen at diagnosis (A), at first recurrence (B), and at autopsy showing collagen deposition in close relationship to blood vessels (C).



the progression of his cancer during bevacizumab therapy, the patient remained stable, with no new neurologic findings and a Karnofsky Performance Scale score of 70.

However, in late December 2012 the patient suddenly died of congestive heart failure and pneumonia—common complications in patients who have had extensive chemotherapy (including one year of temozolomide, one year of bortezomib, and two years continuous bevacizumab treatment). An autopsy showed no active brain tumor (Figures 2 and 4). The cause of death on the autopsy findings was congestive heart failure, pulmonary congestion and edema, and congestive hepatosplenomegaly.

MRI of the brain with and without a contrast agent from March 2012 showed the resection cavity in the patient's left lateral frontal convexity involving his middle frontal gyrus immediately anterior and superior to the pars triangularis (Figure 3). The pars triangularis appeared to be involved with the tumor extending back into the insula and arcuate fasciculus toward the Wernicke area. It also appeared that most of the tumor recurrence was medial and superior to the resection cavity extending toward the ependymal surface of the lateral ventricle and the corpus callosum. The postresection MRI from March 2012 showed partial resection of prior enhancing nodules (Figure 3), with residual FLAIR signal suggestive of residual nonenhancing tumor.

The MRIs obtained at the end of vaccination Cycles 1 through 4 show slowly progressive increase in the FLAIR signal and contrast enhancement around the resection bed (Figure 3). This finding raises the question of tumor progression vs pseudoprogression generated by the immune

inflammation and justifying the need for a biopsy after two vaccination cycles.

The initial immunohistochemical findings of the tumor showed a left frontal GBM with O(6)-methylguanine DNA methyltransferase positivity of 30%, epidermal growth factor receptor (EGFR) positivity of 5%, EGFR variant 3 negative, and phosphatase and tensin homologue 60% of the cells were positive. The specimen collected from the resection before the vaccine administration in March 2012 showed immunohistochemical findings for O(6)-methylguanine DNA methyltransferase of 30%, EGFR of 30%, EGFR variant 3 negative, and phosphatase and tensin homologue of 60%. The tumor had a high Ki-67 index of 15% (Figure 2). The specimen collected after 2 cycles of the vaccine showed scattered lymphocytes, B cells, and macrophages infiltrating the specimen, with a Ki-67 index of 3% to 5% (Figure 4).

Analysis of the autopsy specimen revealed slight vascular endothelial hyperplasia and focally variable permeation by macrophages. Collagen deposition was observed in close relationship with the blood vessels, and there were no definitive Ki-67-positive glioma cells, consistent with a nonproliferating, nonviable tumor (Figures 2 and 4). There was perivascular infiltration of mononuclear inflammatory cells, both T and B lymphocytes (Figures 2 and 4).

DISCUSSION

Recurrence of malignant gliomas after surgery, radiation therapy, and adjuvant chemotherapy is universal.^{4,19} Gross total resection is ineffective in eradicating the entire tumor because of the infiltrative nature of malignant gliomas.⁴ The

only approved treatment for glioblastoma at recurrence is bevacizumab, which was found to have an estimated 6-month progression-free survival rate of 42.6% and an overall survival of 9.2 months.^{20,21} In the end, all GBMs recur during bevacizumab therapy, and the survival after recurrence is usually only a few weeks.⁴

ERC-1671 aims to provide a new and innovative approach to treating patients with GBM. The vaccine is composed of four cycles and includes administration of glioblastoma tumor cell lysates and tumor cells from the patient and three different donors with GBM. With the use of genetically different heterozygous individuals with brain tumors at the time of the vaccine administration, the patient's immune system is exposed to numerous tumor antigens identical to those of the patient's own tumor.⁶ It is as if this action creates a cascade immune response in which the homologous tumor antigens are sequentially recognized by the immune system and eliminated.⁵ In addition, this process also leads to sensitization of the immune system in recognizing cross-reactive allogeneic tumor antigens, enabling the attack of the patient's own brain tumor.^{5,6}

Our patient with confirmed GBM on histopathologic examination received four cycles of the vaccine. He received no other adjuvant chemotherapy or radiotherapy. On the basis of previous experience with patients with GBM, the expected survival after recurrence while the patient is receiving bevacizumab therapy is only a few weeks.²² Our patient survived for ten months without adjuvant chemotherapy. Furthermore, we showed that the tumor displayed less aggressive features throughout the treatment and after completion of the treatment. Figure 2 shows evidence that the tumor's Ki-67 decreased after the patient received the vaccine and completed the treatment. In addition, the blood vessel proliferation and hyperplasia, features of aggressive GBM, slowly receded throughout the treatment (Figure 5). The patient also mounted a strong immune response to the vaccination (Figure 6), as evidenced by T lymphocytes, B cells, and macrophage infiltration of the tumor specimens after completing only two cycles of vaccination, which was evident at the time of autopsy (Figure 5). Similar to our preliminary data in an additional four patients, no clinically significant adverse events were noted with this therapy, and the only side effects noted were mild headaches and local erythema at the injection site.²³

Despite these promising immunologic responses evidenced by histopathologic analysis, the MRI suggested that the patient's tumor appeared to progress. As described by Figure 3, there was increased FLAIR signal as well as increased contrast enhancement around the resection cavity. A possible explanation for these imaging findings could be that our vaccine produced a very strong immune response in the patient, which produced a beneficial inflammation around the tumor bed because of the influx of inflammatory cells in the area. This idea is supported by the histopathologic finding of macrophage, B-cell, and T-cell infiltration found in various tumor specimens obtained from biopsy and autopsy. Hence, proposed criteria related to immune response might represent better measurement of our immune-based therapy.²⁴⁻²⁶ In the

absence of clinical progression, similar imaging changes (pseudoprogression) were previously reported for patients receiving dendritic cell vaccination.²⁷ The inflammatory cytokines could also produce dilation of the blood vessels and shunting of more blood to the involved areas of the brain, thus leading to the enhancement seen on the contrast images.

CONCLUSION

These preliminary observations suggest that ERC-1671 could be effective in the setting of a malignant glioma that has become resistant to the available treatments. However, the effectiveness of this immunotherapeutic approach cannot be established in a pilot study such as this, which had only one patient. Even though no definite conclusions can be made about the efficacy of this treatment, our results indicate that the vaccine was well tolerated, could be safely administered to our patient, and produced promising immunologic responses seen on histopathologic analysis. A larger study to assess how these histopathologic changes clinically benefit our patients with recurrent GBM is being planned. ❖

Disclosure Statement

Dr Bota is a consultant for Novocure; she has received research support from Epitopeic Research Corporation. Dr Carillo is on the Speakers Bureau of Sigma Tau and Novocure. The author(s) have no other conflicts of interest to disclose.

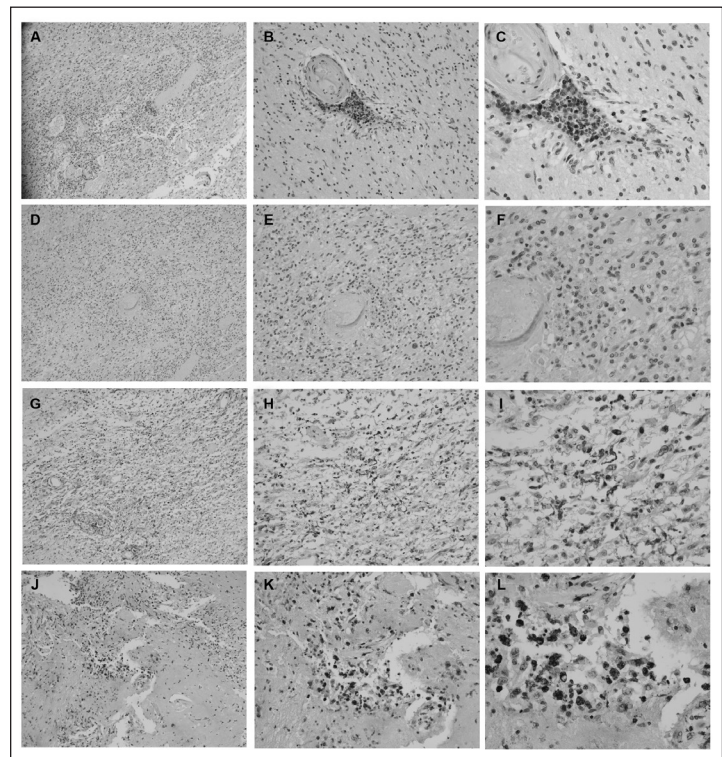


Figure 5. Immunohistochemical staining after 2 cycles of vaccination show CD3⁺ lymphocytes (A-C), CD20⁺ B cells (D-F), and abundant CD68⁺ macrophages (G-I) infiltrating the tumor specimen. Autopsy specimen shows abundant infiltration of tumor cells by CD68⁺ macrophages (J-L).

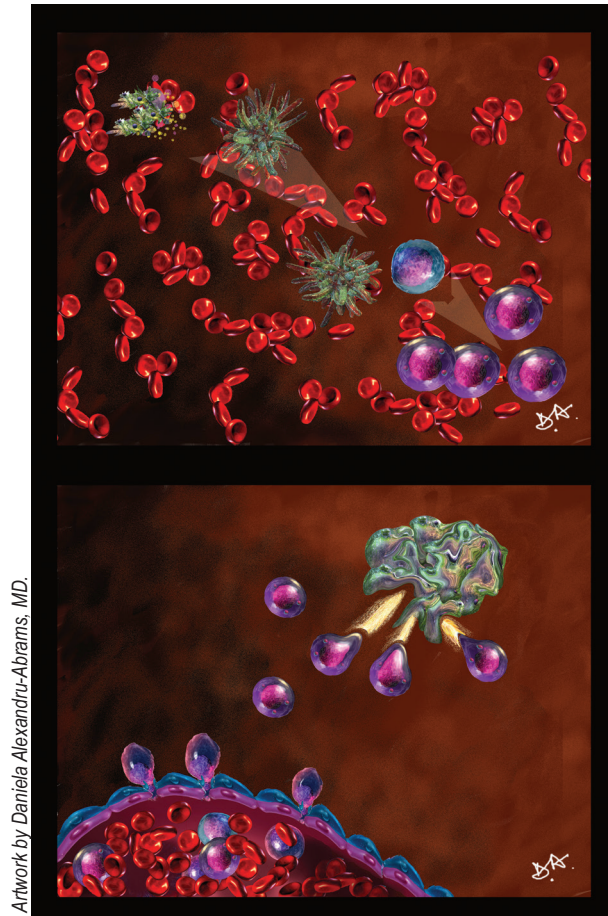


Figure 6. Artist's depiction of vaccination process. Tumor cells and tumor cells' lysate components are injected into the patient, taken up by antigen-presenting cells, and presented to B and T lymphocytes (top). This produces an immune response with activated T cells, which later exude through the capillary endothelial wall into the glioblastoma mass and attack the tumor cells carrying similar antigens (bottom).

Acknowledgment

Kathleen Loudon, ELS, of Loudon Health Communications provided editorial assistance.

References

1. Yamada R, Nakano I. Glioma stem cells: their role in chemoresistance. *World Neurosurg* 2012 Feb;77(2):237-40. DOI: <http://dx.doi.org/10.1016/j.wneu.2012.01.004>.
2. Wick W, Wick A, Weiler M, Weller M. Patterns of progression in malignant glioma following anti-VEGF therapy: perceptions and evidence. *Curr Neurol Neurosci Rep* 2011 Jun;11(3):305-12. DOI: <http://dx.doi.org/10.1007/s11910-011-0184-0>.
3. Stupp R, Mason WP, van den Bent MJ, et al; European Organisation for Research and Treatment of Cancer Brain Tumor and Radiotherapy Groups; National Cancer Institute of Canada Clinical Trials Group. Radiotherapy plus concomitant and adjuvant temozolomide for glioblastoma. *New Engl J Med* 2005 Mar 10;352(10):987-96. DOI: <http://dx.doi.org/10.1056/NEJMoa043330>.
4. Gong X, Schwartz PH, Linskey ME, Bota DA. Neural stem/progenitors and glioma stem-like cells have differential sensitivity to chemotherapy. *Neurology* 2011 Mar 29;76(13):1126-34. DOI: <http://dx.doi.org/10.1212/WNL.0b013e318212a89f>.
5. Stathopoulos A, Samuelson C, Milbou G, Hermanne JP, Schijns VE, Chen TC. Therapeutic vaccination against malignant gliomas based on allorecognition and syngeneic tumor antigens: proof of principle in two strains of rat. *Vaccine* 2008 Mar 25;26(14):1764-72. DOI: <http://dx.doi.org/10.1016/j.vaccine.2008.01.039>.
6. Stathopoulos A, Pretto C, Devillers L, et al. Development of immune memory to glial brain tumors after tumor regression induced by immunotherapeutic Toll-like receptor 7/8 activation. *Oncoimmunology* 2012 May 1;1(3):298-305. DOI: <http://dx.doi.org/10.4161/onci.19068>.
7. Liao LM, Black KL, Martin NA, et al. Treatment of a patient by vaccination with autologous dendritic cells pulsed with allogeneic major histocompatibility complex class I-matched tumor peptides. Case report. *Neurosurg Focus* 2000 Dec 15;9(6):e8. DOI: <http://dx.doi.org/10.3171/foc.2000.9.6.9>.
8. Galon J, Costes A, Sanchez-Cabo F, et al. Type, density, and location of immune cells within human colorectal tumors predict clinical outcome. *Science* 2006 Sep 29;313(5795):1960-4. DOI: <http://dx.doi.org/10.1126/science.1129139>.
9. Naito Y, Saito K, Shiiba K, et al. CD8+ T cells infiltrated within cancer cell nests as a prognostic factor in human colorectal cancer. *Cancer Res* 1998 Aug 15;58(16):3491-4.
10. Garcia-Lora A, Algarra I, Garrido F. MHC class I antigens, immune surveillance, and tumor immune escape. *J Cell Physiol* 2003 Jun;195(3):346-55. DOI: <http://dx.doi.org/10.1002/jcp.10290>.
11. Gu Y, Wang C, Roifman CM, Cohen A. Role of MHC class I in immune surveillance of mitochondrial DNA integrity. *J Immunol* 2003 Apr 1;170(7):3603-7. DOI: <http://dx.doi.org/10.4049/jimmunol.170.7.3603>.
12. Suttmuller RP, van Duivenvoorde LM, van Elsas A, et al. Synergism of cytotoxic T lymphocyte-associated antigen 4 blockade and depletion of CD25(+) regulatory T cells in antitumor therapy reveals alternative pathways for suppression of autoreactive cytotoxic T lymphocyte responses. *J Exp Med* 2001 Sep 17;194(6):823-32. DOI: <http://dx.doi.org/10.1084/jem.194.6.823>.
13. Palo J, Duchesne J, Wikström J. Malignant diseases among patients with multiple sclerosis. *J Neurol* 1977 Oct 7;216(3):217-22. DOI: <http://dx.doi.org/10.1007/BF00313623>.
14. Bystryn JC, Rigel D, Friedman RJ, Kopf A. Prognostic significance of hypopigmentation in malignant melanoma. *Arch Dermatol* 1987 Aug;123(8):1053-5. DOI: <http://dx.doi.org/10.1001/archderm.1987.01660320095019>.
15. Hansen MH, Ostenstad B, Sioud M. Antigen-specific IgG antibodies in stage IV long-time survival breast cancer patients. *Mol Med* 2001 Apr;7(4):230-9.
16. Bowles AP Jr, Perkins E. Long-term remission of malignant brain tumors after intracranial infection: a report of four cases. *Neurosurgery* 1999 Mar;44(3):636-42. DOI: <http://dx.doi.org/10.1097/00006123-199903000-00110>.
17. Papachristou DN, Fortner JG. Effect of postoperative wound infection on the course of stage II melanoma. *Cancer* 1979 Mar;43(3):1106-11.
18. Lechler RI, Sykes M, Thomson AW, Turka LA. Organ transplantation—how much of the promise has been realized? *Nat Med* 2005 Jun;11(6):605-13. DOI: <http://dx.doi.org/10.1038/nm1251>.
19. Glas M, Rath BH, Simon M, et al. Residual tumor cells are unique cellular targets in glioblastoma. *Ann Neurol* 2010 Aug;68(2):264-9. DOI: <http://dx.doi.org/10.1002/ana.22036>.
20. Nagane M, Nishikawa R, Narita Y, et al. Phase II study of single-agent bevacizumab in Japanese patients with recurrent malignant glioma. *Jpn J Clin Oncol* 2012 Oct;42(10):887-95. DOI: <http://dx.doi.org/10.1093/jco/hys121>.
21. Lai A, Filka E, McGibbon B, et al. Phase II pilot study of bevacizumab in combination with temozolomide and regional radiation therapy for up-front treatment of patients with newly diagnosed glioblastoma multiforme: interim analysis of safety and tolerability. *Int J Radiat Oncol Biol Phys* 2008 Aug 1;71(5):1372-80. DOI: <http://dx.doi.org/10.1016/j.ijrobp.2007.11.068>.
22. Friedman HS, Prados MD, Wen PY, et al. Bevacizumab alone and in combination with irinotecan in recurrent glioblastoma. *J Clin Oncol* 2009 Oct 1;27(28):4733-40. DOI: <http://dx.doi.org/10.1200/JCO.2008.19.8721>.
23. Bota DA, Pretto C, Hantos P, et al. First report of ERC-1671 (Gliovac) vaccine use in glioblastoma patients with recurrent disease [abstract IT-24]. *Neuro Oncol* 2012 Oct;14(suppl 6):vi48. DOI: <http://dx.doi.org/10.1093/neuonc/nos224>.
24. Wolchok JD, Hoos A, O'Day S, et al. Guidelines for the evaluation of immune therapy activity in solid tumors: immune-related response criteria. *Clin Cancer Res* 2009 Dec 1;15(23):7412-20. DOI: <http://dx.doi.org/10.1158/1078-0432.CCR-09-1624>.
25. Hoos A, Eggermont AM, Janetzki S, et al. Improved endpoints for cancer immunotherapy trials. *J Natl Cancer Inst* 2010 Sep 22;102(18):1388-97. DOI: <http://dx.doi.org/10.1093/jnci/djq310>.
26. Hoos A, Ibrahim R, Korman A, et al. Development of ipilimumab: contribution to a new paradigm for cancer immunotherapy. *Semin Oncol* 2010 Oct;37(5):533-46. DOI: <http://dx.doi.org/10.1053/j.seminoncol.2010.09.015>.
27. Prins RM, Soto H, Konkankit V, et al. Gene expression profile correlates with T-cell infiltration and relative survival in glioblastoma patients vaccinated with dendritic cell immunotherapy. *Clin Cancer Res* 2011 Mar 15;17(6):1603-15. DOI: <http://dx.doi.org/10.1158/1078-0432.CCR-10-2563>.